Quarantine-induced Stress Cardiomyopathy (Takotsubo Syndrome) during the COVID-19 Pandemic

Gassan Moady MD MPH[1,2] and Shaul Atar MD[1,2]

[1]Department of Cardiology, Galilee Medical Center, Nahariya, Israel
[2]Faculty of Medicine in the Galilee, Bar-Ilan University, Safed, Israel

ABSTRACT **Background:** Takotsubo syndrome (TTS) is a non-ischemic cardiomyopathy characterized by an acute reversible left ventricular dysfunction with typical apical ballooning, usually with subsequent complete spontaneous recovery. TTS may be triggered by several physical and emotional stressors. The name Covidsubo was recently adopted to describe this emerging entity. TTS during quarantine may be a reasonable outcome of the overwhelming stress and fear of this pandemic. However, according to the current literature, conflicting results have been reported regarding the incidence of this syndrome during the first wave of the pandemic, and further studies are needed. High index of suspicion is needed to identify patients during the next waves of the pandemic, particularly given the need for minimizing imaging modalities and contact with the patients.

Objectives: To describe two cases of TTS triggered by quarantine during the coronavirus disease-2019 (COVID-19) pandemic.

Methods: Two patients (age 81 years and 70 years) were admitted to our medical center with severe chest pain with normal blood pressure and heart rate.

Results: TTS should always be in the differential diagnosis in patients presenting with chest pain suspected to be from coronary origin. Based on the typical clinical, echocardiographic, and angiographic findings, we assumed TTS.

Conclusions: The only prominent stressor in the two cases in this article was the stress accompanying quarantine.

IMAJ 2021; 23: 149–152

KEY WORDS: coronavirus disease-2019 (COVID-19), echocardiography, stress, quarantine, Takotsubo syndrome (TTS)

Coronavirus disease-2019 (COVID-19) is an infectious disease caused by severe acute respiratory syndrome coronavirus-2 (SARS-CoV-2), which was first described in December 2019 in Wuhan, Hubei, China, and widely spread to become a global pandemic with ongoing medical and economic implications. In an effort to limit the transmission of this pandemic, quarantine and self-isolation have been adopted in several countries. Quarantine used for the prevention of disease spread may be associated with mental stress.

Takotsubo cardiomyopathy (TTS) is characterized by acute reversible left ventricular dysfunction with typicalwall motion abnormality (apical ballooning) without evidence for epicardial obstructive coronary artery disease It may be triggered by several physical and emotional stressors. The name *Covidsubo* was recently adopted to describe this emerging entity. TTS during quarantine may be a reasonable outcome of the overwhelming stress and fear of this pandemic. However, according to the current literature, conflicting results have been reported regarding the incidence of this syndrome during the first wave of the pandemic, and further studies are needed. High index of suspicion is needed to identify patients during the next waves of the pandemic, particularly given the need for minimizing imaging modalities and contact with the patients.

PATIENTS AND METHODS

PATIENT 1

An 81-year-old female admitted to the intensive cardiac care unit (ICCU) with chest pain, which began 2 days prior to her admission. Her past medical history was significant for well-controlled hyperlipidemia and hypothyroidism. The patient did not report any previous cough, dyspnea, or fever. She stated being in a very stressful period during a quarantine in the previous 3 weeks with no contact with her family members.

On admission, her blood pressure was 100/60 mmHg and her heart rate was 100 beats per minute (bpm). Her physical examination was remarkable for apical systolic heart murmur with no signs of heart failure. Blood count and kidney function tests were within normal limits. Troponin I level was high at 3000 ng/L and B-type natriuretic peptide N-terminal pro b-type natriuretic peptide (NT-pro BNP) was 11400 pg/ml. Real-time PCR for COVID-19 from nasal swab was negative. The electrocardiogram showed normal sinus rhythm with diffuse ST segment elevation, most prominent in the anterior leads with no reciprocal changes [Figure 1A]. Echocardiography showed a moderately reduced global systolic left ventricular function with typical pattern of apical ballooning and left ventricular outflow obstruction [Figure1B].

PATIENT 2

A 70-old-female with hypothyroidism and remote history of acute myeloid leukemia that was successfully treated with bone marrow transplantation was admitted with severe chest pain, which started a few hours before her presentation. The patient was in quarantine during the previous 2 weeks with no social interactions, and stated having many fears from the disease. Blood pressure was 170/80 mmHg and heart rate 95 bpm, and her physical examination was within normal limits. Elevated troponin level at 6000 ng/l and NT-pro BNP at 12100 pg/ml was noticed. The echocardiogram showed reduced apical contraction with estimated ejection fraction of 42% and hyperkinetic basal segments of the left ventricle. To rule out acute myocardial infarction, an urgent coronary angiography was conducted, which demonstrated revealed normal arteries.

RESULTS

Basic characteristics and the clinical course of the two patients are provided in Table 1.

PATIENT 1

We proceeded with emergent coronary angiography that was performed via the right radial artery and revealed normal coronary arteries. Basal hypercontractility and apical ballooning were obvious during left ventriculography [Figure 1C]. Based on these findings, a diagnosis of TTS triggered by stress during quarantine period was assumed. The patient required supplemental oxygen and diuretic therapy due to lung congestion. Her condition improved, and 2 days later she was started on beta blockers and discharged 3 days later after near-normalization

Figure 1. Representative images of patient 1

[A] Twelve-lead ECG on presentation showing normal sinus rhythm with diffuse ST segment elevation, most prominent in the anterior leads. Note the absence of reciprocal changes

[B] Apical four chamber view showing typical apical ballooning consistent with TTS, left ventricular outflow obstruction with mitral regurgitation was also observed

[C] Left ventriculogram during catheterization during systole showing typical ballooning

[D] ECG performed 2 days after admission showing partial resolution of the ST elevation. Of note, QT interval was not prolonged in the patient

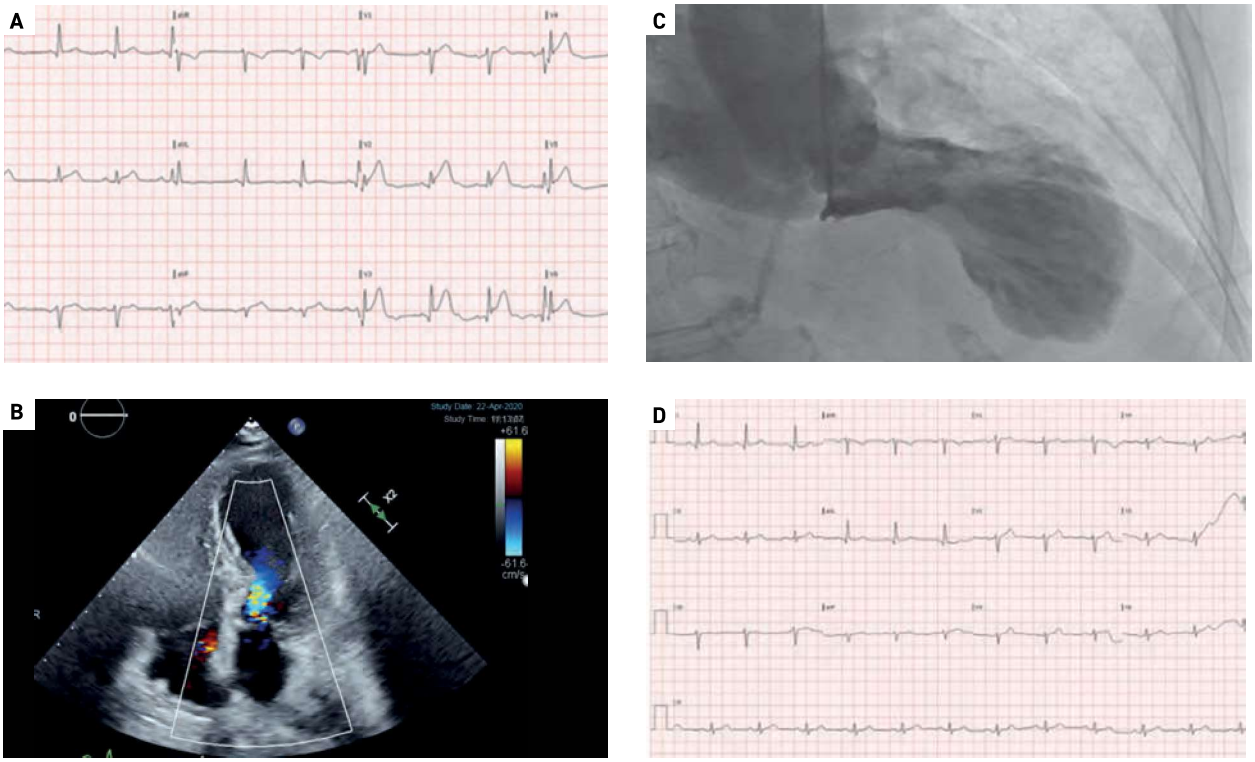

of cardiac function. One month later, complete normalization of the echocardiographic parameters was observed [Figure 1D] and the patient was symptom-free. She was advised for further psychological support during the outbreak.

PATIENT 2

The patient was treated with beta blockers and angiotensin-converting enzyme and was discharged after 5 days with complete recovery of cardiac function. We assumed TTS based on the typical clinical, echocardiographic, and angiographic findings.

DISCUSSION

In addition to its pulmonary complications, the current COVID-19 outbreak has several extra-pulmonary manifestations, including those of the cardiovascular system [1-3]. Quarantine used to limit disease spread across the country is associated with negative psychological effects [4,5]. People in quarantine report high prevalence of depression, stress, insomnia, and anxiety brought on by long durations of quarantine, fear of infection, frustration, and inadequate supplies [6]. Two factors contribute to the development of TTS in

Table 1. Demographic, clinical, laboratory, and echocardiographic data of two patients with Takotsubo syndrome triggered by quarantine-induced stress

Variable	Reference range	Patient 1	Patient 2
Age, years		81	70
Sex		Female	Female
Medical history		Hyperlipidemia, hypothyroidism	Hypothyroidism, remote history of acute myeloid leukemia
Chronic medications		Eltroxin	Eltroxin, statin
Duration of quarantine		3 weeks	2 weeks
Presenting symptoms		Chest pain radiating to neck	Chest pain radiating to left shoulder with dyspnea
Physical examination		BP 100/60 mm Hg, HR 100 beats/min	BP 170/80 mm Hg, HR 95 beats/min
Transthoracic echocardiographic findings on admission		Moderately reduced left ventricular systolic function (EF 38%), moderate to severe mitral regurgitation due to dynamic subaortic obstruction, apical ballooning.	Mildly reduced left ventricular systolic function (EF 42%) with apical ballooning and hyperkinetic basal segments.
ECG		NSR with anterior ST segment elevation.	NSR with anterior ST segment elevation.
Values at admission			
Creatinine (mg/dl)	0.57–1.11	1.19	0.97
Troponin (ng/l)	< 20	3000	6000
NT pro BNP (pg/ml)	< 125	11400	12100
Coronary angiography		Patent coronaries	Patent coronaries
Treatment during hospitalization		Beta blockers and ACE inhibitors	Beta blockers and ACE inhibitors
Complications		Dynamic LVOT obstruction	Right groin hematoma after catheterization
Length of stay		3 days	5 days
Transthoracic echocardiographic findings on discharge		EF 44% with mild apical hypokinesia without LVOT obstruction	Normal cardiac anatomy and function

ACE = angiotensin-converting enzyme, BP = blood pressure, HR = heart rate, EF = ejection fraction, ECG = electrocardiogram, NSR = normal sinus rhythm, NT pro BNP N = B-type natriuretic peptide N-terminal pro b-type natriuretic peptide, LVOT = left ventricular outflow tract

this setting: the quarantine regime itself is associated with stress and many of the self-isolated individuals are elderly with co-morbidities who are already are at increased risk of developing TTS.

Several triggers have been reported in TTS including infection, anxiety, grief, surgery, public speaking, general anesthesia, and even happy events [7-9].

We described two cases of TTS induced by quarantine stress. The two patients denied any exposure to COVID-19 and had no symptoms of cough, fever, or shortness of breath. In addition, they tested negative for COVID-19 by nasopharyngeal swab real-time reverse transcription polymerase chain reaction. Myocardial injury is well documented in COVID-19 patients, and its severity ranges from asymptomatic biomarker elevation to fulminant myocarditis [10].

Myocarditis should be included in the differential diagnosis in cases of suspected TTS. However, TTS can be differentiated from myocarditis when the echocardiography shows typical apical ballooning such as in our cases. In addition, myocarditis causing cardiac dysfunction is typically associated with high levels of troponin while patients with TTS generally have relatively mildly elevated troponin and extremely high natriuretic peptide levels.

Currently, several cases of TTS have been reported as a consequence of depression and stress during quarantine and self isolation [11-14]. Trends toward increased incidence of TTS during the first wave were noticed in a retrospective study by Jabri et al. [15]. In this study, patients with TTS had longer hospital length of stay compared to patients in the pre-pandemic era; however, with no difference in the clinical presentation, mortality rates, or 30-days re-hospitalization. According to our local registries, 6 to 8 definitive cases of TTS (based on the current accepted criteria) have been documented in the last 5 years.

In comparison, during the quarantine during the first wave of the pandemic, four cases were documented (two with clear evidence of quarantine induced stress). Worldwide, the true incidence of TTS induced by quarantine stress is not clearly determined yet and controversial results have been reported. It is reasonable to expect higher incidence of this syndrome due to the increased stress during this pandemic. Our cases, together with the emerging evidence on quarantine induced TTS, highlight the importance of high index of suspicion for this syndrome during the current pandemic. Future registries may determine the true impact of quarantine during the COVID-19 outbreak and the true global change in incidence of TTS. Remote medicine may play an essential role in attenuating the stress among quarantined people. Subsequently, it may lead to better satisfaction and patient quality of life [16]. Theoretically, this may help to decrease the incidence of stress-related disorders, including TTS.

CONCLUSIONS

Quarantine used to prevent the current COVID-19 spread may trigger several stress-induced diseases including TTS. High index of suspicion for this syndrome is required among elderly patients with chest pain.

Correspondence

Dr. G. Moady
Dept. of Cardiology, Galilee Medical Center, Nahariya 22100, Israel
Phone: (972-4) 910-7273, (972-4) 910-7438
Fax: (972-4) 910-7279
email: gassan_muady1@hotmail.com

References

1. Zhou F, Yu T, Du R, et al. Clinical course and risk factors for mortality of adult in patients with COVID-19 in Wuhan, China: a retrospective cohort study. *Lancet* 2020; 395 (10229): 1054-62.
2. Wang D, Hu B, Hu C, et al. Clinical characteristics of 138 hospitalized patients with 2019 novel coronavirus-infected pneumonia in Wuhan, China. *JAMA* 2020; 323 (11): 1061-9.
3. Guan WJ, Ni ZY, Hu Y, et al. Clinical characteristics of coronavirus disease 2019 in China. *N Engl J Med* 2020; 382 (18): 1708-20.
4. Mattioli AV, Ballerini Puviani M, Nasi M, Farinetti A. COVID-19 pandemic: the effects of quarantine on cardiovascular risk. *Eur J Clin Nutr* 2020; 74 (6): 852-5.
5. Parmet WE, Sinha MS. Covid-19 - the law and limits of quarantine. *N Engl J Med* 2020; 382 (15): e28.
6. Brooks SK, Webster RK, Smith LE, et al. The psychological impact of quarantine and how to reduce it: rapid review of the evidence. *Lancet* 2020; 395 (10227): 912-20.
7. Templin C, Ghadri JR, Diekmann J, et al. Clinical features and outcomes of Takotsubo (stress) cardiomyopathy. N Engl J Med 2015; 373 (10): 929-38.
8. Kato K, Di Vece D, Cammann VL, et al; InterTAK Collaborators. Takotsubo recurrence: morphological types and triggers and identification of risk factors. *J Am Coll Cardiol* 2019; 73 (8): 982-4.
9. Medina de Chazal H, Del Buono MG, Keyser-Marcus L, et al. Stress cardiomyopathy diagnosis and treatment: JACC state-of-the-art review. *J Am Coll Cardiol* 2018; 72 (16): 1955-71.
10. Babapoor-Farrokhran S, Gill D, Walker J, Rasekhi RT, Bozorgnia B, Amanullah A. Myocardial injury and COVID-19: possible mechanisms. *Life Sci* 2020; 253: 117723.
11. Chadha S. 'COVID-19 pandemic' anxiety-induced Takotsubo cardiomyopathy. *QJM* 2020; 113 (7): 488-90
12. Rivers J, Ihle JF. COVID-19 social isolation-induced Takotsubo cardiomyopathy. *Med J Aust* 2020; 213 (7): 336-336.e1.
13. Giannitsi S, Tsinivizov P, Poulimenos LE, et al. [Case Report] Stress induced (Takotsubo) cardiomyopathy triggered by the COVID-19 pandemic. *Exp Ther Med* 2020; 20 (3): 2812-14.
14. Koutroumpakis E, Taylor T, Damaraju S, Badruddin Mawji S. "Covidsubo": stress-induced cardiomyopathy by novel coronavirus disease 2019. *Cardiology* 2020; 145 (12): 779-83.
15. Jabri A, Kalra A, Kumar A, et al. Incidence of stress cardiomyopathy during the coronavirus disease 2019 pandemic. *JAMA Netw Open* 2020; 3 (7): e2014780.
16. Gamus A, Chodick G. Telemedicine after COVID-19: The Israeli perspective. *IMAJ* 2020; 8 (22): 401-3.

What a strange machine man is!
You fill him with bread, wine, fish, and radishes, and out come sighs, laughter, and dreams.
Nikos Kazantzakis (1883–1957), Greek poet and novelist