Treatment of Peripheral Nerve Injuries in Syria's War Victims: Experience from a Northern Israeli Hospital

Sorin Daniel Iordache MD[1,4], Albert Gorski MD[2,5], Marwa Nahas MSc (OT) MHA[3,5], Lior Feintuch MD[2,5], Nimrod Rahamimov MD[2,5], and Tal Frenkel Rutenberg MD[1,4]

[1]Department of Orthopedic Surgery and Traumatology, Rabin Medical Center (Beilinson Campus), Petah Tikva, Israel
Departments of [2]Orthopedic Surgery and [3]Occupational Therapy, Western Galilee Hospital, Nahariya, Israel
[4]Sackler Faculty of Medicine, Tel Aviv University, Tel Aviv, Israel
[5]Azrieli Faculty of Medicine, Bar Ilan University, Safed, Israel

ABSTRACT **Background:** The collapse of the Syrian healthcare system during the civil war led numerous citizens to cross the Syrian–Israeli border to seek medical care.

Objectives: To describe the epidemiology of peripheral nerve injuries (PNIs) sustained in war, their management, and short-term outcomes.

Methods: A retrospective case series study was conducted on 45 consecutive patients aged 25.7 ± 9.3 years. These patients were referred to the hand surgery unit of the department of orthopedic surgery and traumatology at Galilee Medical Center between December 2014 and June 2018. Median time between injury and presentation was 60 days. Injury pattern, additional injuries, surgical findings and management, complications, and length of hospital stay were extracted from medical records.

Results: Most injuries were blast (55.6%) followed by gunshot injuries (37.8%). There were 9 brachial plexus injuries, 9 sciatic nerve injuries, and 38 PNIs distal to the plexus: specifically 20 ulnar, 11 median, and 7 radial nerve injuries. In the latter group, neurotmesis or axonotmesis was found in 29 nerves. Coaptation was possible in 21 nerves necessitating cable grafting in 19. A tendon transfer was performed for 13 peripheral nerves, occasionally supplementing the nerve repair. The patients returned to their country after discharge, average follow-up was 53.6 ± 49.6 days.

Conclusions: For nerve injuries sustained in war, early surgical treatment providing adequate soft tissue conditions is recommended. Tendon transfers are useful to regain early function.

IMAJ 2021; 23: 279–285

KEY WORDS: nerve lesion, peripheral nerve injury, Syrian refugees, upper extremity trauma, war surgery

For editorial see page 323

The 8-year long civil war in Syria led to the complete collapse of the local healthcare system. According to several United Nations reports, by the end of 2017, more than 12.8 million people were in need of medical assistance [1,2]. Under these conditions, numerous Syrian citizens, many of them severely wounded, sought medical care across the Israeli border [3]. The majority of these patients were treated at the Galilee Medical Center, in northern Israel.

Over 75% of war injuries are to the extremities and up to 30% of the injuries to the extremities are peripheral nerve injuries (PNIs) [4-6]. These injuries occur either directly, when a penetrating projectile contacts the nerve, or indirectly due to heat and shockwave damage to the tissue [5]. While some injuries might improve spontaneously, the majority will require surgical treatment [5,6].

As warfare technology advances, the patterns of injuries sustained in war change accordingly. In this study we report the epidemiology of peripheral nerve injuries in modern conflicts as reflected in the civil war in Syria and our unique experience in treating such injuries in the challenging population crossing the border to seek medical care.

PATIENTS AND METHODS

This study was approved by the Galilee Medical Center institution review board. Data were retrospectively collected from medical records of 98 successive wounded Syrian patients who sustained limb injuries and were referred to the hand surgery unit of the department of orthopedic surgery and traumatology at Galilee Medical Center between December 2014 and June 2018.

Patient's demographics, time from injury to presentation, injury pattern, additional injuries, surgical findings and management, bacterial growth from wounds, and length of hospital stay were extracted from medical records. For patients who received medical attention before crossing the border, recoding of previous procedure was completed when possible.

Additional injuries to the head region and torso were described as well as injuries of the ipsilateral limb. During surgery, injuries were further classified by the International Committee of the Red Cross Wound Score (RCWS) [7].

Nerve lesions were classified according to Seddon's method [8]. The classification was performed by combining clinical findings with surgical observations. Nerves that looked

intact on visual inspection but had no function were classified as neuropraxia. Partial thickness nerve injuries in which at least some remaining healthy fascicles were observed crossing the lesion, were classified as axonotmesis. Complete nerve injuries were defined as neurotmesis. In addition, nerve lesions were classified according to Birch et al. [9] who simplifies peripheral nerve injury classification into two categories: degenerative (i.e., axonotmesis) and non-degenerative (mainly as persistent conduction block).

Since crossing the border was fraught with difficulties for these patients and there was little hope they could return for outpatient care after the initial surgical treatment, the patients were admitted for as long as necessary to reconstruct a functional limb, including a rehabilitation program. At the end of treatment, the patients were discharged and returned to Syria.

RESULTS

We identified 45 patients with peripheral nerve injuries, 42 males and three females, the mean age was 25.7± 9.3 years (range 7–52 years). The median time between injury and presentation was 60 days (mean 140.7 ± 204.3, range 2 days to 3 years) and the average in-hospital follow-up was 53.6 ± 49.6 days (range 6–248 days). Four patients returned to the hospital following discharge, three for additional related procedures and one for an unrelated medical cause. For two additional patients video footage demonstrating limb function was sent from Syria and was available for review. For these six patients, the total follow-up duration was 13.3 ± 4 months (303–637 days).

SEVERITY OF INJURIES

Most injuries were blast (25) and gunshot injuries (17). The remaining were the result of a motor vehicle accident (two) and of an unsuccessful ulnar nerve grafting performed elsewhere (one). Seventeen patients presented with multiple systemic injuries [Table 1]. Twenty-eight patients presented with isolated limb trauma, mostly the upper limb (21 patients).

Associated injuries in the ipsilateral upper limbs are described in Table 1. Thirteen patients had additional bone injury, eight presented with vascular injury and seven with extensive soft tissue damage. The Red Cross Wound Entry Transfer was used to further grade the injuries; four patients had sustained a grade 1 (low energy) injury, and three patients had a grade 3 (massive energy transfer) injury grade. As most patients presented more than 14 days following injury, and some following initial surgical intervention in Syria, we were only able to classify seven patients according to the RCWS.

The distribution of the nerve injuries was as follows: in the upper limb, nine patients had brachial plexus injuries, and 27 patients had 38 peripheral upper limb nerves injuries. In the lower limb, nine patients had sciatic nerve injuries.

Table 1. Associated systemic injuries and injuries to the ipsilateral limb

Associated injuries		Number of patients
Associated systemic injuries*		
Thoracic injuries		9
Head trauma		5
Facial fractures and eye injuries		4
Abdominal trauma		3
Pelvic trauma (including perineum and buttocks)		3
Sepsis		2
Vascular injury		2 critical, 6 noncritical
Acute renal failure		1
Spinal fracture		1
Upper limb fracture**		21
Lower limb fracture**		10
Penetrating neck injury		1
Burns		2
Associated ipsilateral limb injuries		
Bone	Fractures of ulna/radius	6 (2 with segmental fractures)
	Fractures of humerus	5 (3 with segmental fractures)
	Ankylosis elbow	1
	Radioulnar synostosis	1
Vascular	Noncritical radial or ulnar artery lesion	5
	Critical brachial	1
	Critical radial and ulnar	1
Soft tissue defect	Forearm	3
	Arm	2
	Loss of fifth ray	1
Infection	Infection deep to the fascia	6 (including osteomyelitis in 1)

*A single patient could have presented with several injuries
**Several injuries in the same limb segment were counted as one (e.g., ulna and radius fractures or tibia and fibula fracture or several hand bones fractures due to crush). Fracture of different segments, such as arm and forearm, were considered different fractures.

TREATMENT

Forty-four patients were treated surgically: 27 underwent a single surgical procedure for exploration and treatment of the nerve injuries. Seventeen patients underwent multiple procedures (mean 4.1 ± 2.1, range 2–8) when wound debridement, fracture fixation, and soft tissue flap coverage were needed before the nerve repair. One patient was treated non-surgically.

BRACHIAL PLEXUS INJURIES

Patients who presented with brachial plexus injuries were treated within 236.1 ± 124 days from the injury (range 30–480) [Table 2]. Three patients underwent tendon transfers, three underwent neurotization, one neurolysis, and one nerve repair with sural nerve cable grafts. The last patient was a 12-year-old boy who sustained a gunshot injury that ruptured his subclavian artery and vein and caused an infraclavicular medial and lateral cord injury. The patient was operated initially in Syria, his medial clavicle was removed, and the subclavian artery and vein were ligated. With a rehabilitation program the patient regained motor grade +3/5function of his shoulder and elbow early after the injury, and we decided against an intervention. We had a long-term follow-up for only one patient who sustained a blast injury and had a C6-T1 plexus injury. At exploration the nerves were found to be continuous and a neurolysis was performed. By eight months post operatively he demonstrated a good 4/5 elbow function in a short video he sent for the follow-up.

PERIPHERAL UPPER LIMB INJURIES

Upper limb PNIs distal to the plexus were treated on an average of 145.8 ± 243.6 days from the injury (range 2 days to 3 years). Twenty-seven patients were treated for 38 complete upper limb peripheral nerve injuries, specifically 20 ulnar (8 high and 12 low), 11 median (4 high and 7 low), and 7 radial (4 high and 3 low) nerve injuries. Five nerves were considered unrepairable, either due to the local soft tissue conditions or the time from injury. In those cases, we proceeded directly with tendon transfers. Thirty-three nerves were explored. The findings are described in Table 3.

SCIATIC NERVE INJURIES

Nine patients presented with sciatic nerve injuries, three in the level of the buttocks and six in the thigh. Four patients had residual tibial division function (weak foot or finger flexion 3/5) at presentation. No patient had any function in the peroneal division.

All lower limb injuries were treated surgically, 58.4 ± 49.5 days from the injury (range 4–150 days). Of the nine lower limb injuries, four were found to be complete transections (neurotmesis) and three partial injuries (axonotmesis). Two nerves were found to be continuous during surgery (neuropraxia).. Treatment included graft coaptations of the entire nerve or of the specific disrupted fascicles in seven patients and neurolysis in two patients. None of the patients with a residual motor function deteriorated after surgery. Four patients, two with neuropraxia and two with axonotmesis, had a minor improvement of 2/5 in additional tibial innervated muscles

Table 2. Treatment modalities for brachial plexus injuries

Patient	Age	Pattern	Time to treat (days)	Treatment	Details
SA	38	C5-C7	420	Tendon Transfer	- Inferior trapezius to infraspinatus - Unipolar trapezius to biceps - FCU to ECRB passive pinch
HI	31	C8-T1	360	Tendon Transfer	- FDS opponensplasty - Zancoli passive claw
MS	19	Infraclavicular	248	Tendon Transfer	- FCR to ECRB - House I passive pinch
HA	20	Infraclavicular	150	Cable Grafting	- Ulnar nerve - Median nerve
MA	20	C5-C6	70	Neurotization and neurolysis	Spinal accessory to supraspinatus
BB	20	C5-C7	320	Neurotization	- Spinal accessory to supraspinatus - Oberlin Transfer
RA	21	Pan-plexus	210	Neurotization	- Spinal accessory to supraspinatus - Intercostals to musculocutaneous
HH	32	C6-T1	111	Neurolysis	
AKM	12	C5-T1		Physiotherapy	

FCU = flexor carpi ulnaris, ECRB = extensor carpi radialis brevis, FDS = flexor digitorum superficialis, FCR = flexor carpi radialis

Table 3. Peripheral nerve injuries

Explored nerves	Findings at exploration	Diagnosis	Treatment
9	Normal epineurium	Neuropraxia	Neurolysis
3	Fibrotic over a long segment	Neurotmesis	Tendon transfers
2	Well established complete neuroma	Neurotmesis	Coaptation with cable grafts
5	Damaged epineurium with partial fascicular injury at exploration	Axonotmesis	Coaptation and cable grafting of the involved fascicles
14	Nerve ruptured with a gap	Neurotmesis	Coaptation with cable grafts

a few days after the procedure. We had long-term follow-up for one patient with neuropraxia who underwent neurolysis and had improved to 4/5 sciatic nerve function one year after the procedure.

INFECTIONS

Seventeen of the 45 patients, mainly the multi-trauma patients, were treated for infections in various sites during their admission. The bacterial flora isolated in these patients included multiple drug resistant bacteria such MRSA and multi drug resistant gram-negative roods such as *Acinetobacter baumannii*, *Klebsiella pneumonia*, or *Pseudomonas Aeruginosa* Only four patients were treated for an infection at the site of the nerve injury before the operation.

COMPLICATIONS

We lost three nerve repairs to infections. All cases were complex and all patients underwent multiple procedures before the nerve repair including multiple debridements, a free fibula graft, a groin flap, and tendon transfers due to soft tissue loss. We were able to redo a median nerve repair in one patient. A second was treated with tendon transfers. A third with a high ulnar palsy declined an additional procedure given the risk of recurrent infection.

REOPERATIONS

Three patients underwent revisions. The first presented 4 months following a blast injury at the level of the elbow, with ulnar nerve injury. He was initially treated with a combined coaptation of the ulnar nerve and neurotization of the anterior interosseous nerve to the ulnar motor branch at the wrist. While his hypothenar muscles did not become atrophic, clawing remained, and one year later an additional tendon transfer was performed. The second patient presented 37 days after sustaining a gunshot wound to the elbow. He had complete ulnar nerve palsy and incomplete median nerve palsy. While the median nerve improved without intervention, cable grafting was used for the ulnar nerve. Seven months later he returned with an abscess at the surgical site. As ulnar function had not recovered, a debridement and tendon transfer were performed. The last patient presented 12 days following a gunshot wound to the arm with median nerve and a non-critical brachial artery injury. The initial exploration showed a partial median nerve injury and the transected fascicles were repaired with an interposition graft. The artery was repaired with a reverse saphenous vein graft. One year later there was only minimal anterior interosseous nerve (AIN) function and a revision was performed, including flexor policis longus shortening and a tendon transfer (FDP four–five to FDP two–three).

DISCUSSION

We present the epidemiology of peripheral nerve injuries in 45 consecutive patients injured in the Syrian civil war. Nearly half of the patients had additional major injuries to other organ systems. Most limb injuries were high grade, the majority were in the upper limb. PNI treatment included neurolyses, nerve coaptations, the majority necessitating cable grafting, neurotizations and tendon transfers.

The prevalence of peripheral nerve injuries in our cohort is similar to the outcomes described by Razaq et al. in Pakistan [10], yet some diversity in specific PNIs exist [6,11,12]. This variety might be the result of similar injury mechanism in all studies, as blast injuries were the main cause of trauma in most groups [6,10,12], followed by gunshot wounds [10,11]. Generally, differences in prevalence can be explained by local warfare preferences, patterns of referral, and by conditions causing delay in patient transportation, as patients who present with delay have a higher chance of being amputated in proximity to the injury prior to the medical transfer to a tertiary facility [13,14].

El Hajj Abdallah and colleagues [11] described neurological injuries caused by the Syrian civil war, as observed in a rehabilitation center near the Turkish and Syrian border. The authors also described peripheral nerve injuries to be the most common neurological injury. Like our situation, the authors were also unable to follow their patients after discharge, as Syria is a combat zone with limited resources. In our study, however, we could increase accuracy of the reported injuries by provide intraoperative findings as opposed to clinical examinations and electromyographys. We could also report the short-term surgical outcomes to add to the information obtained in the previous study.

We have divided our patients to three main groups of nerve injuries, peripheral nerve injuries, brachial plexus injuries and sciatic nerve injuries.

In our study, for the PNI group, nerve repair was attempted when bone and soft tissue could support such treatments. To achieve optimal conditions, bone stabilization and recurrent debridements were often performed, and flaps were used when tissue coverage did not suffice. Only a few nerves were treated with direct suture repair in our series, like others who reported 14% direct nerve repairs [5,15], while most coaptations required nerve grafts. This result is related to the delayed presentation of the patients who were required to flee the war zone in Syria and cross the border prior to receiving treatment at our hospitals. We

are aware that the prolong duration that elapsed between injury and presentation did not affect solely the treatment strategy, as primary nerve repair was often unfeasible, but could have also influenced outcomes. If routine follow-up was possible, some patients would have probably required additional surgery, such as secondary tendon transfers.

The expected limited rehabilitation and lack of future follow-up influenced the choice of treatment, encouraging tendon transfers over neurotization, as results are more reliable and predictable and recovery time is shorter [16]. In five patients who presented either too late or when the soft tissue damage was too extensive, we skipped the nerve exploration and performed primary tendon transfers. In other patients, when the expected time to recovery after nerve coaptation was expected to be prolonged, we performed secondary tendon transfers together with the nerve repairs, using Bruckhalter's internal splinting for radial nerve, and EIP opponensplasty and claw hand repairs for high median and ulnar nerves. The aim was to provide early function with the tendon transfers and hope that this function will improve gradually as the nerve recovers. Neurotization of AIN to the ulnar motor branch could have been used more often as a supercharging technique in patients with isolated high ulnar nerve injuries, and today we use the technique routinely in these cases.

For PNI, we recommend early exploration even when the injury was the result of a gunshot wound or a blast, as new injuries are easier to mend before scars and neuromas are formed. In this study we found that 29 of the 38 nerves (76%) were ruptured or had severe axonal injury at exploration leading to the conclusion that the chance of spontaneous recovery is low and prolonged waiting is unnecessary. We also found that even in the early days following the trauma, one can assess whether the nerve is intact or not by exploring it. If the epineurium was breached even minimally by the projectile or the blast, we opened it and explored the fascicles. Visual inspection provided information about the extent of injury and in several cases, we debrided and repaired only the torn fascicles [Figures 1A-1F].

Figure 1. A 25-year-old patient, presented 2 days following a gunshot Injury to his arm. Initially, exploration demonstrated a presumably intact median nerve, yet a profound exploration has revealed an extensive injury to the fascicles, treated with interposition grafting.

[A] Gunshot wound to the arm

[B] Damaged epineurium evident at initial inspection

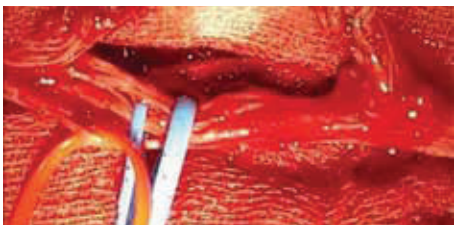

[C] At exploration 50% of the nerve fascicles were ruptured

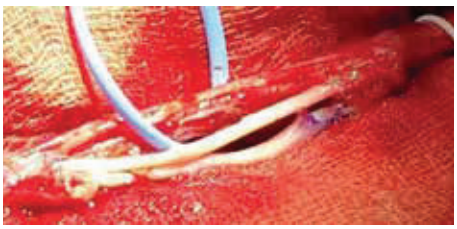

[D] The involved fascicles were debrided and coaptation with sural nerve grafts was performed

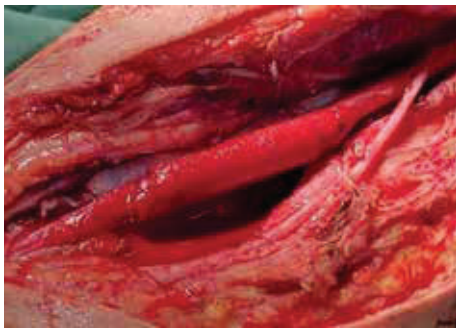

[E] A collagen tube nerve protector was used to protect the repair

[F] The patient at 18-month follow-up: no anterior interosseous nerve function

[G] The patient at 18-month follow-up with median good sensation and preserved opposition

Brachial plexus injuries were noted in nine patients, eight of which underwent surgery. Generally, due to the delay presentation of most patients (311 ± 84 days), we used neurotizations when repairs weren't feasible believing they may provide function or enable a better choice of tendon transfers in the future. When it was possible, we performed tendon transfers opting for early function as being essential for patients returning to a country with no medical services to speak of.

A similar rate of sciatic nerve injuries was noted in our study as well as that of Razaq et al. in Pakistan [10]: approximately 16%. All of our patients who presented with sciatic nerve injuries were treated surgically. As the sciatic nerve is large, we found a partial injury in three nerves. In these three patients and in two patients with an intact nerve, we believe that a component of conduction block was common, since they showed minor improvements as early as days after surgery. None demonstrated neurological deterioration following surgery. Therefore, we recommend early exploration for this injury as well.

The average admission length in this cohort was 53 days and up to six months in severely injured patients. A significant factor in these circumstances was to balance the medical needs such as controlling infections and obtaining tissue equilibrium for nerve repairs with the patients' desire to return to their families as soon as possible, all this while healing and obtaining useful hand function. In order to shorten their admission time, patients worked closely with occupational therapists and physiotherapists to reduce the tissue swelling improve the range of motion as we tried to diminish the time between procedures to the minimum. We also used the admission time for rehabilitation and the patients were thought how to perform ADL and advanced ADL at their current functioning level and in face of the expected nerve deficiency.

LIMITATIONS

Follow-up duration was short and did not continue after discharge, yet hospitalization was long and allowed for some rehabilitation and follow-up. Second, as only the patients who were able to cross the border in seek of medical attention were reviewed, our data does not represent the more severely injured patients who were unable to endure the journey. Finally, considering the severity of the trauma to the affected limbs, and the additional soft tissue, vascular, and bone injuries, it seems surprising that only three patients underwent revision surgeries. However, this finding could be misleading due to the follow-up bias.

Wartime crossing of international borders for medical care presents unique challenges to both caregiver and patient. Language and religious barriers, lack of crucial medical history, inability to follow patients after discharge, lack of communication with future medical service providers, and above all lack of family support require re-thinking and preplanning of treatment to better accommodate these unusual circumstances [17,18].

CONCLUSIONS

This study describes our unique approach and experience with peripheral nerve injuries in the Syrian civil war cross-border patients. Most patients presented with delay, had multi-organism infections and inadequate pre-admission treatment with no medical history or documentation. We found that with surgical intervention the complication rate was low and none of our patients deteriorated neurologically following surgery. In an attempt to balance the need to return the patients as soon as possible to their friends and families with the understanding this is a "one shot" hospitalization that needs to include all interventions, we performed nerve repairs and coaptations when indicated and opted for tendon transfers when we considered the chances of nerve recovery to be low. We believe that early nerve surgery is easier and that operating on gunshot and blast wounds early improves outcomes, providing that the soft tissue conditions are reasonable.

Correspondence

Dr. T. Frenkel Rutenberg
Dept. of Orthopedic Surgery and Traumatology, Rabin Medical Center (Beilinson Campus), Petah Tikva, 49191 Israel
email: tal_frenkel@hotmail.com

References

1. Devi S. Syria: 7 years into a civil war. *Lancet* (London, England) 2018; 391: 15-6.
2. Martinez JC, Eng B. Stifling stateness: The Assad regime's campaign against rebel governance. *Secur Dialogue* 2018; 49: 235-53.
3. Zarka S. The medical humanitarian face of Israel. *IMAJ* 2019; 21: 165-8.
4. Zeljko B, Lovrc Z, Amc E, Busic V, Lovrc L, Markovc I. War injuries of the extremities: twelve-year follow-up data. *Mil Med* 2006; 171: 55-7.
5. Secer HI, Daneyemez M, Tehli O, Gonul E, Izci Y. The clinical, electrophysiologic, and surgical characteristics of peripheral nerve injuries caused by gunshot wounds in adults: a 40-year experience. *Surg Neurol* 2008; 69: 143-52; discussion 152.
6. Birch R, Misra P, Stewart MPM, et al. Nerve injuries sustained during warfare: part I--Epidemiology. *J Bone Joint Surg Br* 2012; 94: 523-8.
7. Coupland RM. The Red Cross classification of war wounds: the E.X.C.F.V.M. scoring system. *World J Surg* 1992; 16: 910-7.
8. Sunderland S. A classification of peripheral nerve injuries producing loss of function. *Brain* 1951; 74: 491-516.
9. Birch R. Operating on peripheral nerves. In: Dyck PJ TP, editor. Peripher. neuropathy. 4th ed., Philadelphia: Elsevier Saunders; 2005: 1511-32.
10. Razaq S, Yasmeen R, Butt AW, Akhtar N, Mansoor SN. The pattern of peripheral nerve injuries among Pakistani soldiers in the war against terror. *J Coll Physicians Surg Pak* 2015; 25: 363-6.
11. El Hajj Abdallah Y, Beveridge J, Chan M, et al. Devastating neurologic injuries in the Syrian war. *Neurol Clin Pract* 2019; 9: 9-15.
12. Vrebalov-Cindro V, Reic P, Ognjenovic M, et al. Peripheral nerve war injuries. *Mil Med* 1999; 164: 351-2.
13. Mathieu L, Bertani A, Gaillard C, Chaudier P, Ollat D, Bauer B, et al. Combat-related upper extremity injuries: surgical management specificities on the theatres of operations. *Chir Main* 2014; 33.
14. Belmont PJ, Owens BD, Schoenfeld AJ. Musculoskeletal Injuries in Iraq and Afghanistan: epidemiology and outcomes following a decade of war. *J Am Acad Orthop Surg* 2016; 24: 341-8.
15. Roganovic Z. Missile-caused median nerve injuries: results of 81 repairs. *Surg Neurol* 2005; 63: 410-9.
16. Compton J, Owens J, Day M, Caldwell L. Systematic review of tendon transfer versus nerve transfer for the restoration of wrist extension in isolated traumatic

radial nerve palsy. *J Am Acad Orthop Surg Glob Res Rev* 2018; 2: e001.

17. Doner P, Ozkara A, Kahveci R. Syrian refugees in Turkey: numbers and emotions. *Lancet* (London, England) 2013; 382: 764.

18. Duramaz A, Bilgili MG, Bayram B, Ziroglu N, Bayrak A, Avkan MC. Orthopedic trauma surgery and hospital cost analysis in refugees; the effect of the Syrian civil War. *Int Orthop* 2017; 41: 877-84.

Capsule

Resistance of SARS-CoV-2 variants to neutralization by monoclonal and serum-derived polyclonal antibodies

Severe acute respiratory syndrome coronavirus-2 (SARS-CoV-2) has caused the global COVID-19 pandemic. Rapidly spreading SARS-CoV-2 variants may jeopardize newly introduced antibody and vaccine countermeasures. Using monoclonal antibodies (mAbs), animal immune sera, human convalescent sera and human sera from recipients of the BNT162b2 mRNA vaccine, **Chen** et al. reported the impact on antibody neutralization of a panel of authentic SARS-CoV-2 variants including a B.1.1.7 isolate, chimeric strains with South African or Brazilian spike genes and isogenic recombinant viral variants. Many highly neutralizing mAbs engaging the receptor-binding domain or N-terminal domain and most convalescent sera and mRNA vaccine-induced immune sera showed reduced inhibitory activity against viruses containing an E484K spike mutation. As antibodies binding to spike receptor-binding domain and N-terminal domain demonstrate diminished neutralization potency in vitro against some emerging variants, updated mAb cocktails targeting highly conserved regions, enhancement of mAb potency or adjustments to the spike sequences of vaccines may be needed to prevent loss of protection in vivo.

Nature Med 2021; 27: 717
Eitan Israeli

Capsule

Developing an immunotherapy for AD

Hyperphosphorylated tau aggregates contribute to neurodegeneration in patients with Alzheimer's disease (AD), and reducing tau accumulation has had therapeutic effects in preclinical models. **Ayalon** and colleagues generated and characterized a humanized anti-tau monoclonal antibody called semorinemab, which they tested in mice and nonhuman primates and in a phase 1 clinical trial in humans. Semorinemab was able to bind all six human tau isoforms and had therapeutic effects in vivo in AD mice by reducing tau accumulation. In patients with AD, semorinemab crossed the blood-brain barrier and showed evidence of target engagement without evident side effects. These results support the idea that immunotherapies targeting tau might be effective in reducing tau pathology in AD.

Sci Transl Med 2021; 13: eabb2639
Eitan Israeli

Capsule

Building back colonic crypts

Restoration of the colonic epithelium after mucosal injury depends on cell renewal initiated by intestinal stem cells (ISCs) and their progeny. Stromal cells near the base of colonic crypts secrete trophic factors for ISCs, but regulation of this process by proinflammatory mediators is not well understood. **Cox** and co-authors used mouse models of pathogen- or chemical-induced epithelial damage to investigate the contribution of interleukin-1 (IL-1) and its receptor (IL-1R1) to epithelial restitution. IL-1 release set off a signaling pathway supporting ISC renewal and proliferation and promoted innate lymphoid cell production of IL-22, a cytokine supporting colonocyte proliferation. These findings illustrate the need to consider the desirable regenerative properties of IL-1 when designing therapeutic approaches for chronic inflammatory diseases.

Sci Immunol 2021; 6: eabe8856
Eitan Israeli