"One Health" Approach to Rickettsiosis - Case Report

Authors:

Gabriela Kleinerman DVM, PhD [1],

Sivan Melloul DVM [1],

Alon Abramovich MD [1],

Sagi Gavriel PhD [1],

Lavie Haim DVM [1],

Affiliations:

[1] Medical Corps, IDF.

Corresponding Author:

Gabriela Kleinerman

gabriela.kleinerman@mail.huji.ac.il

To cite this article:

Kleinerman G, Melloul S, Abramovich A, Gavriel S, Haim L. "One Health" Approach to Rickettsiosis – Case Report. J Isr Mil Med, June 2021, 18 (50): 46-43.

ABSTRACT

Rickettsiosis is an important vector-borne infection of humans in Israel. In the IDF, an average incidence of 3.3 cases per 100,000 soldiers is reported annually (5.5 times higher than in civilians). We applied the "One Health" approach to address a murine typhus case in a reserve soldier who was infected during a field training, for: the purpose of risk assessment and determination of preventative measures for future Rickettsiosis infections. A multidisciplinary team from the IDF Medical Corps evaluated the area and collected ticks and fleas from the vegetation and a *Meriones tristami* gerbil. Out of the 21 ticks collected, one contained *Rickettsia typhi*-DNA, making this the first report of a *Rhipicephalus sanguineus* tick harboring typhus group Rickettsial DNA in Israel. None of the 15 fleas were infected. Due to the low prevalence of *Rickettsia* infection in the ticks and the fact that they were only found in a small area of the military base, it was decided to carry out training of recruits as planned and not implement pest control. Several measures were taken to prevent the occurrence of new cases of Rickettsiosis, such as: use of insect repellent, examination of the soldiers for presence of tick and flea bites at the end of the training, and antibiotic prophylactic antibiotic if arthropod bites were found.

The multidisciplinary approach used in this study resulted in a valuable exchange of capabilities, necessary for preventive science-based decision making concerning an area which is an important military training site and naturally protected.

Background: Rickettsioses are vector-borne diseases caused by obligate intracellular bacteria belonging to the genus *Rickettsia* [1]. They are divided into two main groups: the spotted fever group rickettsiosis (SFGR) transmitted mainly by ticks, including *Rickettsia conorii israelensis* among others; and the *typhus* group rickettsiosis (TGR) transmitted mainly by fleas, including *Rickettsia felis* typhi [2]. SFGR and TGR are both characterized by high fever, headaches, rashes, and myalgia. In addition, TGR can present with digestive and neurological signs [2]. *Rickettsia felis* is the etiological agent of flea-borne spotted fever, with symptoms that resemble murine typhus (TGR) [3]. In the Israeli military health services, reports of Rickettsiosis include both SFGR and TGR, and the average annual incidence from 2007 to 2017 was 3.5/100,000 soldiers, while in civilians the incidence was 0.6/100,000 individuals. The U.S military health system reported annual incidence averages of 80.7/100,000 and 4.6/100,000 soldiers from 2010 to 2018 of SFGT and TGR, respectively (https://www.health.mil/News/Articles/2019/08/01/Incidence-of-Rickettsial-Diseases). Concerning SFGR, the incidence was 80 times higher than in US civilians (1.2/100,000 individuals) (https://www.cdc.gov/rmsf/stats/index.html).

Keywords: Rickettsiosis, Rickettsia typhi, Rhipicephalus sanguineous, "One Health".

The "One Health" concept aims to attain optimal health for people, animals and our environment through a cross-sectoral coordinated response [4]. The occurrence of Rickettsiosis in a reserve soldier following a training exercise required the implementation of this approach in the form of risk assessment and preventive decision-making in order to avoid future pathogen spillover from animals to humans.

Case report

A 39-year-old reserve soldier was admitted to the emergency department of the Sheba Medical Center, with a four-day history of fever, headaches, eye pain, tinnitus, hearing loss, and dizziness. He reported the presence of ticks on his clothes ten days prior to the onset of symptoms, during training activities in areas with shrubs. Entrance to caves, contact with water sources and traveling to other countries were ruled out as potential causes. During the physical examination, he showed sensitivity to eye movement, conjunctivitis and fever (39.3 °C). A chest radiograph, an abdominal ultrasound and a head CT did not show irregularities. A lumbar puncture revealed clear CSF with no proteins or cell multiplication. Blood tests indicated thrombocytopenia (108,000 per microL), increased bilirubin and creatinine levels (1.63 mg\dL and 1.8 mg\dL, respectively), elevated liver enzymes (AST=108 IU\l, ALT=87 IU\l and GGT=149 IU\l) and CRP of 255 mg\L. Hepatitis A, B and C were tested and ruled out. The differential diagnosis included rickettsiosis and Q fever. An antibiotic treatment of Doxycycline and Ceftriaxone was started, with subsequent clinical and laboratory recovery of the patient. He was discharged after a four-day hospitalization with outpatient follow-up and continuation of Doxycycline treatment orally (200 mg a day for 3 days). A blood sample was taken to the Israeli reference laboratory for rickettsial diseases, where they performed an indirect fluorescent antibody serological test (IFA) for spotted fever, murine typhus and Q fever. The results showed IgG titers of 3200 and high IgM titers for *R. typhi* and borderline IgM and IgG titers of 400 corresponding to *R. conorii*. Antibody titers (IgG and IgM) for *Coxiella burnetii* (phase I and II) were negative.

The following actions were taken to determine if the exposure site was safe for future training: first, an interdisciplinary team composed of an entomologist, two veterinarians and a paramedic explored the area to identify possible tick or flea-infested spots. In a second visit, hard ticks were collected using the 'dragging' technique, where a cloth was dragged across the top of the vegetation to catch questing ticks. The surveyed spots included the surroundings of the dormitories, the kitchen and dining room, and the dunes where most of the training took place. Furthermore, twenty Sherman traps were distributed along the dune area to trap *Meriones tristrami* ("Tristram's jird"), a rodent commonly found in coastal and semi-desert parts of Israel which is considered an invasive species by the Ministry of Environmental Protection (https://www.gov.il/en/departments/legalInfo/extermination_law).

Following the trapping of the rodents, fleas and ticks were collected from the animals. Ticks were sent to the "Kimron" veterinary institute for morphological identification and were then taken together with the fleas to the Israeli reference laboratory for rickettsial diseases, for molecular detection of *Rickettsia* spp. DNA was extracted from individual questing ticks using a commercial kit (Qiagen, Germany) following the manufacturer's protocol. The ticks and fleas collected from the Tristram's jird were analyzed by pools (two pools of 15 flies and 7 ticks, respectively) using the same kit. A nested PCR targeting the 17-kD gene was performed to identify the genus *Rickettsia* on the ticks and fleas' DNA as described previously [5]. The nested PCR was followed by a restriction fragment length polymorphism (RFLP) test aimed to discriminate between SFGR and TGR, according to previous publication [5].

The exposure site is located in a commando unit's military base, in a naturally protected area on the Israel coastal line. Fourteen *Rhipicephalus sanguineous* were collected from the vegetation in the dune area. In addition, one *M. tristami* was captured, fifteen fleas were collected by brushing its fur and 7 *R. sanguineous* ticks were obtained manually from its body. One out of 14 (7.1%) questing ticks was positive for TGR by RFLP, showing three DNA segments corresponding to *R. typhi* digestion pattern following previous publication (127 base pairs -bp-, 50 bp and 37 bp) (figure 1) [5]. Both pools of ticks and fleas collected from the jird were negative by PCR.

Considering the low prevalence of infection of *Rickettsia* spp. found in the ticks (less than 5% of all the ticks collected), in addition to the fact that only a certain area of the base was infested with ticks and only one wild rodent was captured, the IDF animal and pest control division decided not to

Figure 1:

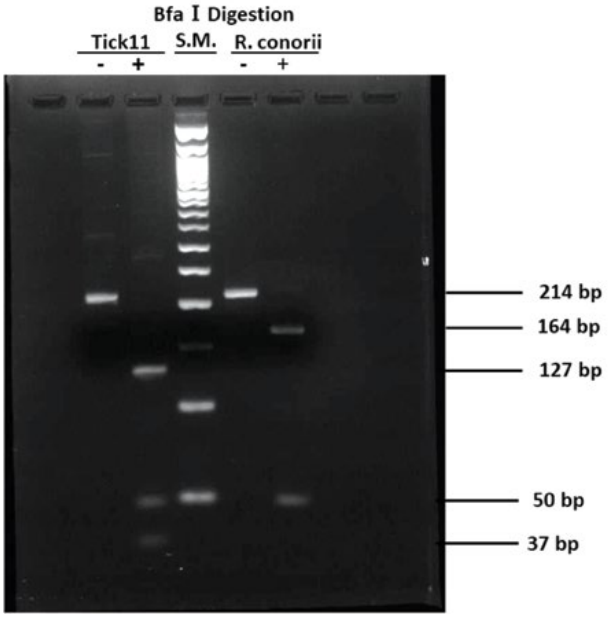

Analysis of Rickettsia 17-kD nested PCR products by restriction fragment length polymorphism test, by means of BfaI digestion of *R. conorii* and a nested PCR product of a (*Rickettsia* spp.) positive questing tick (tick 11), the gel electrophoresis analysis was done on a 10% polyacrylamide gel. SM = XIII size markers (Boehringer); *R. conorii* (Moroccan strain). + = digested with BfaI; – = undigested. BfaI digestion of *R. conorii* (SFGR) resulted in the generation of two fragments (164 bp and 50 bp), while BfaI digestion of tick No. 11 harboring Rickettsial DNA resulted in the generation of three fragments (127 bp, 50bp, and 37bp), which matches *R. typhi* (TGR) pattern according to Leitner et al. 2002.

carry out pest control. Future training of recruits was performed as planned with the following measures implemented to prevent tick and flea bites:

1. use of insect repellent (DEET)
2. a thorough examination of all soldiers for tick and flea bites at the end of the training,
3. if bites were observed, a Doxycycline prophylactic treatment was started (200 mg the first day, 100 mg for the next four days) and
3. raising awareness of clinical symptoms such as fever during the first two weeks after the exposure.

Discussion

In this case report, we describe the occurrence of a case of TGR on a reserve soldier who was bitten by an arthropod during a training session. We implemented a "One Health" approach to make preventive health decisions regarding an area which is an important military training site and is a nature reserve, harboring valuable autochthonous flora and fauna.

Although the clinical presentation at the time of admission included only two out of three symptoms of the traditional triad of TGR (fever, headache and skin rash), the rapid clinical response to doxycycline raised the suspicion of a *Rickettsia* infection. The IFA serology test showing high titers for *R. typhi* (8-fold higher than *R. conorii*), confirmed a murine typhus-like infection.

Rats are the animal reservoir of *R. typhi* [2]. We did not observe rat burrows in the dunes where the patient was bitten; therefore, it is possible that another *Rickettsia*, causing a disease resembling murine typhus, may have been the cause of the illness. *R. felis* DNA was first detected in Israel in the serum of a patient suffering from splenic infarction, which was misdiagnosed as murine typhus by serological tests at the time of the disease [6]. *R. felis* was associated with neurological signs (bilateral hearing loss, dizziness), conjunctivitis and photophobia [7] and is known to produce cross-reaction in serological tests between SFGR and TGR. This *Rickettsia* is associated mainly with cat fleas but has also been found in flea species of wild rodents [8]; therefore, it is possible that the reserve soldier was infected with *R. felis* through the bite of a flea from a wild rodent.

In this study, we describe the first report of a TGR DNA in a *R. sanguineous* in Israel. *R. sanguineous* feeds mainly on dogs; however, it can feed on other hosts such as rodents, birds and humans [9]. This tick can transmit: *Babesia vogeli*, *Ehrlichia canis*, *Hepatozoon canis*, *Rickettsia conorii* and *Rickettsia ricketsii* among other pathogens [9]. The patient reported the presence of ticks on his body; thus, it is also possible that the patient was infected with a 'flea-transmitted' *Rickettsia* through the bite of a hard tick which acquired the *Rickettsia* from a previous rodent blood meal. *R. felis* and *R. typhi*, both transmitted by fleas, were found in *R. sanguineous* ticks in Brazil and Mexico [10, 11].

The prevalence of TGR and SFGR infection in questing ticks was of 7% and 0%, respectively. Previous studies

performed in Israel reported a higher rate of infection of SFGR in *Riphicephalus* spp. ticks (between 10.5 to 38%) [12, 13]. Even though the tick collection in our study was performed in the peak of the questing tick season (between March and June), the prevalence of *Rickettsia* infection in the ticks was low [14]. It is important, nevertheless, to perform analysis of wild rodents, fleas, and questing ticks on a broader scope in order to have a better picture of the epidemiology of Rickettsiosis in this rich ecosystem.

There is no IDF antibiotic protocol for hard tick bites. However, considering that the area is endemic for SFGR and TGR, we decided on starting doxycycline prophylaxis treatment whenever tick or flea bites were observed, following a previous recommendation [15]. No new cases of Rickettsiosis were reported in this area during the writing of this manuscript, proving the importance of a multidisciplinary approach for the management of zoonotic vector-borne diseases with a complex epidemiology. The cooperation of veterinarians, physicians, entomologists and biologists from different organizations led to a valuable exchange of capabilities and information which is necessary for preventive decision making. This is an example of a successful collaboration that serves the "One Health" initiative for prevention of new cases of infectious diseases.

Acknowledgments

We thank Asael Roth from the Kimron Veterinary Institute for the morphologic identification of ticks and Adi Beth-Din from the Israel Institute for Biological Research for her assistance in the serological and molecular analysis.

REFERENCES

[1]. Raoult D, Roux V. Rickettsioses as Paradigms of New or Emerging Infectious Diseases. Clin Microbiol Rev 1997;10(4):694-719.

[2]. Parola P, Paddock CD, Raoult D. Tick-Borne Rickettsioses Around the World: Emerging Diseases Challenging Old Concepts. Clin Microbiol Rev 2005; 18(4):719–756.

[3]. Bouyer DH, Stenos J, Crocquet-Valdes P et al. *Rickettsia felis:* Molecular Characterization of a New Member of the Spotted Fever Group . Int J Syst Evol Microbiol 2001;51(2),339–347.

[4]. Kelly TR, Machalaba C, Karesh WB et al. Implementing One Health Approaches to Confront Emerging and Re-Emerging Zoonotic Disease Threats: Lessons From PREDICT. One Health Outlook 2020;10;2:1.

[5]. Leitner M, Yitzhaki S, Rzotkiewicz S, Keysary A. Polymerase Chain Reaction-Based Diagnosis of Mediterranean Spotted Fever in Serum and Tissue Samples. Am J Trop Med Hyg 2002;67(2):166-169.

[6]. Ben-Zvi I, Meltzer E, Nogueras MM, et al. First Detection of Human Infection With *Rickettsia felis* in Israel. Am J Med Sci 2010;340(4),343.

[7]. Zavala-Velázquez JE, Ruiz-Sosa JA, Sánchez-Elias RA, et al. *Rickettsia felis* Rickettsiosis in Yucatán. Lancet 2000;356(9235):1079-1080.

[8]. Pérez-Osorio CE, Zavala-Velázquez JE, Arias León JJ, Zavala-Castro JE. *Rickettsia Felis* as Emergent Global Threat for Humans. Emerg Infect Dis. 2008;14(7):1019-1023.

[9]. Dantas-Torres F, Otranto D. *Rhipicephalus sanguineus* s.l. (Latreille, 1806). In Estrada-Peña A, ed. Ticks of Europe and North Africa, Springer International Publishing AG, Switzerland; 2018:323-327.

[10]. Oliveira KA, Oliveira LS, Dias CCA, et al. Molecular Identification of *Rickettsia felis* in Ticks and Fleas From an Endemic Area for Brazilian Spotted Fever. Mem Inst Oswaldo Cruz. 2008;103(2):191-194.

[11]. Dzul-Rosado K, Lugo-Caballero C, Raul Tello-Martin R, et al. Direct Evidence of Rickettsia Typhi Infection in *Rhipicephalus Sanguineus* Ticks and Their Canine Hosts. Open Vet J 2017;7(2):165-169.

[12]. Harrus S, Perlman-Avrahami A, Mumcuoglu KY, et al. Molecular Detection of *Rickettsia massiliae, Rickettsia sibirica mongolitimonae* and *Rickettsia conorii israelensis* in Ticks From Israel. Clin Microbiol Infect 2011; 17(2):176–180.

[13]. Rose J, Nachum-Biala Y, Mumcuoglu KY, et al. Genetic Characterization of Spotted Fever Group Rickettsiae in Questing Ixodid Ticks Collected in Israel and Environmental Risk Factors for Their Infection. Parasitology 2017;144(8):1088-1101.

[14]. Lalzar I, Harrus S, Mumcuoglu KY, Gottlieb Y. Composition and Seasonal Variation of Rhipicephalus Turanicus and *Rhipicephalus Sanguineus* Bacterial Communities. Appl Environ Microbiol. 2012;78(12):4110-4116.

[15]. Kenyon RH, Williams RG, Oster CN, Pedersen Jr CE. Prophylactic Treatment of Rocky Mountain Spotted Fever. J Clin Microbiol. 1978;8(1):102-104.