Computed Tomography-Guided Placement of Sacral Electrodes

Ada Rosen MD[1,4], Sorin Elias MD[2,4], Hadas Ganer Herman MD[3,4], Alexander Condrea MD[3,4], and Shimon Ginath MD[3,4]

Departments of [1]Surgery A and Proctology, [2]Radiology and [3]Obstetrics and Gynecology, Wolfson Medical Center, Holon, Israel
[4]Sackler Faculty of Medicine, Tel Aviv University, Tel Aviv, Israel

ABSTRACT **Background:** The current approach to performing sacral neuromodulation consists of a two-stage procedure, the first of which includes insertion of the sacral electrode under fluoroscopic visualization of the S3 foramen. Alternatively, in certain situations computed tomography (CT)-guided insertion can be used.

Objectives: To evaluate the use of CT in cases of reinsertion of the electrode due to infection, dislocation, or rupture.

Methods: Medical records of patients who underwent neuromodulation device reinsertion between 2005 and 2016 for fecal incontinence were reviewed. Study outcomes included procedure course, successful placement, and long-term treatment success.

Results: During the study period, we inserted a neuromodulation device in 67 patients. A CT-guided insertion of a sacral electrode was performed in 10 patients. In nine patients, the insertion and the final location of the electrode were successful. In one patient, the electrode migrated upward due to a malformation of the S3 foramen on both sides and had to be placed in S4. In a mean follow-up of 68.4 ± 30.0 months following the re-insertion, there was a significant reduction in the number of incontinence episodes per day ($P < 0.001$) and the number of pads used per day ($P = 0.002$).

Conclusions: CT-guided insertion of a sacral electrode is a safe and promising option, especially in recurrent and or selected cases.

IMAJ 2021; 23: 773–776

KEY WORDS: computed tomography (CT)-guided; neuromodulation, reinsertion; sacral electrode

Sacral neuromodulation (SNM) is a therapeutic option for pelvic pain, overactive bladder, urinary retention, fecal incontinence, constipation, and double incontinence [1].

The current approach to sacral nerve stimulation consists of a two-stage procedure. The first is a percutaneous nerve evaluation (PNE) test for 10–14 days. If successful, the second stage, which includes permanent implantation, is conducted [2,3]. The PNE test is performed in most centers under fluoroscopic visualization of the S3 foramen. This technique has some limitations, such as operator radiation exposure, poor visualization of the sacral foramen due to bowel gas artifacts, or technical difficulty in cases of sacral malformation [4].

To reduce these inconveniences and to improve the efficiency of electrode insertion, an alternative technique is necessary. Some authors reported the use of CT-guided insertion [5,6], O-arm guided imaging, which combines intraoperative fluoroscopy with the capability of multi-dimensional imaging [7] and ultrasound [8].

The use of CT could potentially be of use in every PNE, yet the procedure is often less feasible, since the CT is not located in the operating theater and the cost is higher than fluoroscopy. Thus, we employed a protocol for the use of CT only in cases of reinsertion of the electrode due to infection, dislocation, anatomic malformation, or rupture.

The objective of this study was to evaluate the efficacy of CT use in cases of reinsertion.

PATIENTS AND METHODS

For the purpose of the study, the cases of patients who had a sacral stimulator E on mini 3788™ (St. Jude Medical, MN, USA) implanted between January 2005 and December 2016 at the Wolfson Medical Center were reviewed, and cases necessitating reimplantation were included. The method of insertion was implemented previously [3].

Using CT guidance, under local anesthesia, a 21-gauge needle was inserted through the skin and positioned in the right or left S3 sacral foramen as a marker. The introducer needle of the sacral stimulation device was then inserted instead, through the foramen [Figure 1], and a guide was inserted through the needle [Figure 2]. The exact location and depth were confirmed by CT and marked on the guide. At this point, the patient was taken to the operating theater. The guide was removed and replaced by the sacral electrode. The depth of the electrode was confirmed definitively by stimulation, patient sensation in the anal and perineal region, and by anal sphincter contraction. No fluoroscopy was used. The electrode was then connected to the permanent or temporary stimulator.

The inclusion criteria of patients comprised of fecal incontinence (> 1/week), soiling, overactive bladder, urge/frequency,

Figure 1. Multiplanar reconstruction of computed tomography images in coronal **[A]** and sagittal **[B]** view of introducer needle in both sides (white arrows), yellow arrows demonstrate the subcutaneous portion of the previous electrode

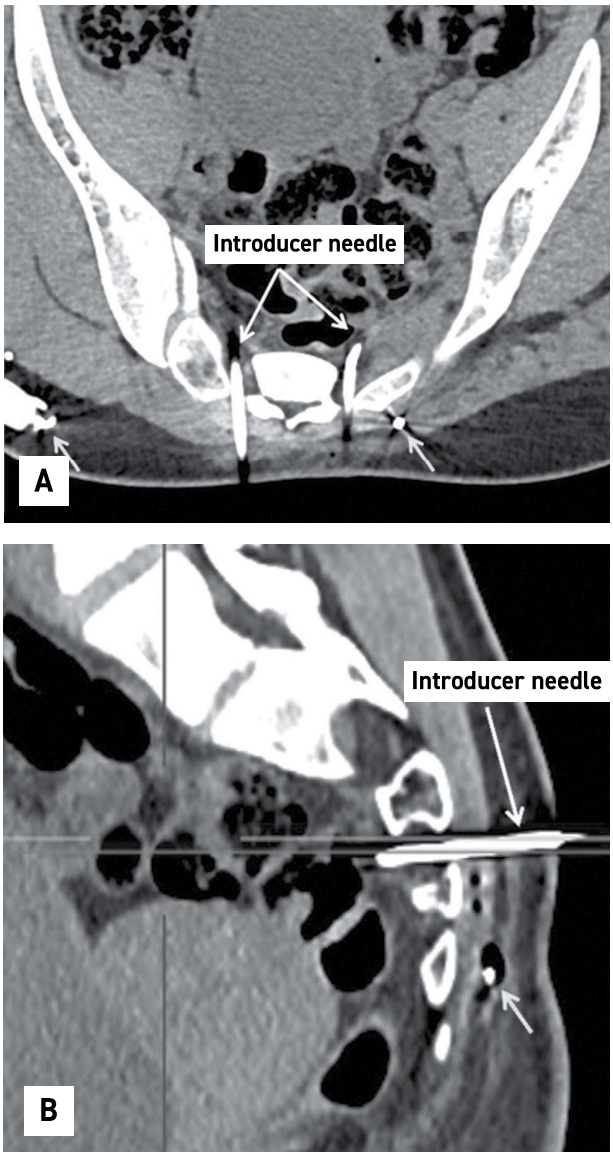

Figure 2. Volumetric rendering technique reconstruction of computed tomography images in lateral **[A]**, posteroanterior **[B]**, and anteroposterior **[C]** view demonstrate the in depth guide insertion through the introducer needle

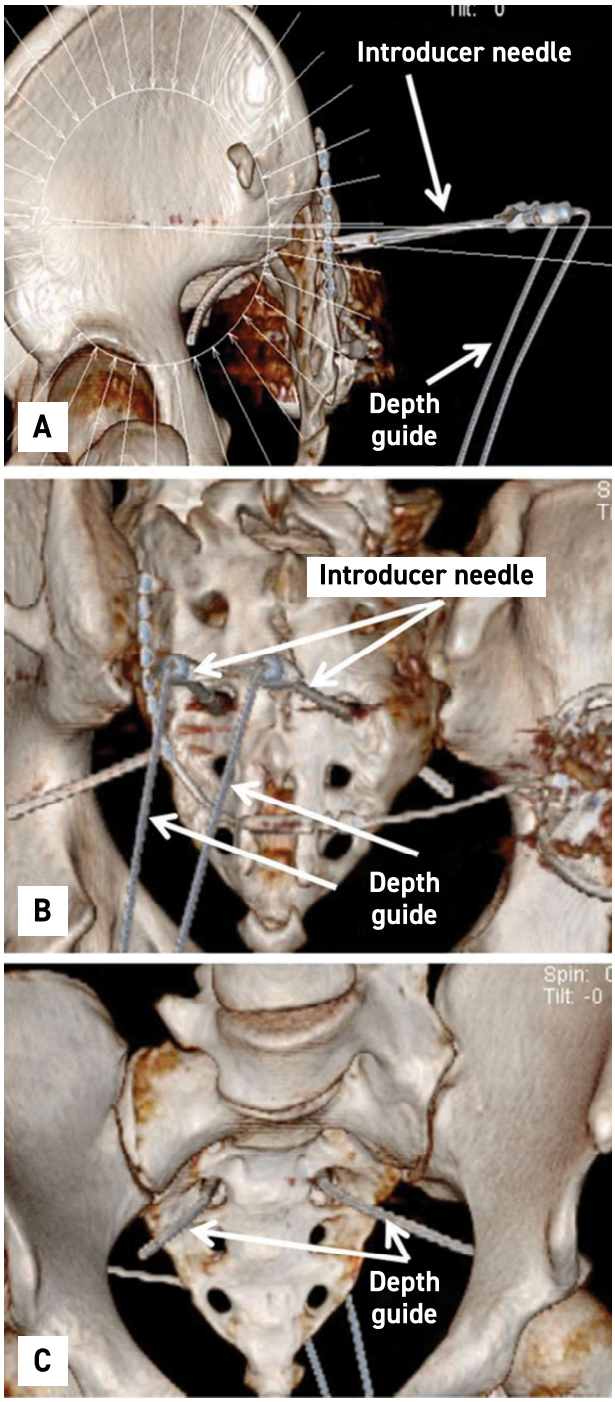

urge incontinence, and/or congenital rectal malformations. Exclusion criteria were patients with presence of full-thickness rectal prolapse, chronic diarrhea (unmanageable by diet or drugs), constipation, urinary retention, presence of pelvic pain only, stoma in situ, bleeding complications, pregnancy, anatomical limitations preventing placement, or skin/tissue disease that would significantly increase the risk of infection. Patient data were collected from medical charts and including age, sex, reasons for CT-guided insertion, and time from original insertion to CT-guided insertion. The quality of life of the patients was evaluated according to the parameters listed in the Cleveland Clinic Florida (Wexner) fecal incontinence score. Treatment efficacy was assessed by the number of fecal incontinence (solid, liquid, and/or gas) episodes per day and the number of pads used per day.

Table 1. Patient characteristics

Patient No.	Age (year)	Sex	Complain	Cause of CT guided insertion	Time from original insertion to CT guided insertion (months)
1	45	Female	Urinary incontinence	Dislodgment	24
2	72	Male	Fecal incontinence	Dislodgment	9
3	58	Female	Fecal incontinence	Dislodgment	24
4	62	Female	Fecal incontinence	Dislodgment	15
5	61	Female	Fecal incontinence	Dislodgment	14
6	45	Male	Fecal incontinence	Infection	13
7	71	Female	Fecal incontinence	Rupture of electrode	18
8	17	Female	Fecal incontinence	Dislodgment	19
9	78	Female	Fecal incontinence	Malformation	2
10	76	Female	Fecal incontinence	Lack of response	2
Mean ± standard deviatoin	58.5 ± 18.7				14.0 ± 7.9

CT = computed tomography

STATISTICAL ANALYSIS

Continuous variables were calculated as mean ± standard deviation or median and range, as appropriate. Categorical variables were calculated as rate (%). A *t*-test was used to compare continuous parameters. Statistical significance was considered at $P < 0.05$. Statistical analyses were performed using IBM Statistical Package for the Social Sciences statistics software, version 18 (SPSS, IBM Corp, Armonk, NY, USA). Institutional review board approval was obtained for the study (0008-16-WOMC).

RESULTS

During the study period, we implanted a sacral stimulator in 76 patients with pelvic pain and/or fecal and/or urinary incontinence, who did not improve with medical, behavioral, or biofeedback therapy. Of these, 59 patients (78%) subsequently underwent permanent implantation. Ten patients needed a reinsertion of the electrode due to infection, malformation, loss of sensation, or rupture. In these patients, we used the CT-guided insertion, and they constituted the study group.

Eight study patients were women and two were men. The mean age was 58.5 ± 18.7 years (ranging 17 to 78 years). In eight patients, CT-guided reinsertion was performed with a permanent stimulator because of electrode dislodgement in six patients, infection in one patient, and rupture of the electrode in one patient. In two patients, CT-guided reinsertion was performed with a temporary stimulator due to lack of response to stimulation in one patient and an anatomic malformation of the S3 foramen in the other one [Table 1]. In the last patient, since the electrode migrated upward due to a malformation of the S3 foramen on both sides, it was repositioned to S4 [Figure 3]. The two temporary implants were subsequently replaced with a permanent one.

Figure 3. Multiplanar reconstruction of computed tomography images in sagittal view of introducer needle inserted to S4 due to the malformation of the S3 foramen on both sides heading the electrode upward

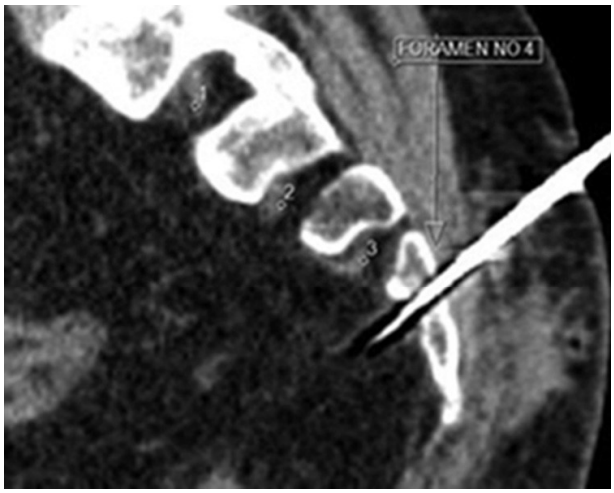

During the mean follow-up of 68.4 ± 30.0 months following the reinsertion, there was a significant reduction in the number of incontinence episodes per day ($P < 0.001$), and the number of pads used per day ($P = 0.002$) [Table 2].

DISCUSSION

In this study, we showed successful re-implantation of permanent electrodes by CT guidance due to dislodgment, infection, malformations, loss of sensation, or rupture.

SNM therapy is considered as an alternative therapeutic option for pelvic pain and urinary and bowel control for patients with overactive bladder, urinary retention, fecal incontinence,

constipation, or double incontinence. SNM modulates the neural reflexes that influence the bladder, urethral and anal sphincters, and pelvic floor [1].

Our approach for SNM consists of a two-stage procedure, as described in a previous report [3].

The PNE test is performed under fluoroscopic control using the palpable bony sacral foramina as referral points. This technique is not without limitations, such as operator radiation exposure, poor visualization of the sacral foramina due to bowel gas artifacts, and technical difficulty in cases of sacral malformation. Yet, it is inexpensive and easy to use in almost any operating theater. To reduce these inconveniences and to improve the efficacy of this modality, some authors have reported alternative techniques using ultrasound or CT [2]. A thick and dense subcutaneous tissue could be considered a limiting condition for ultrasound-guided lead placement due to the difficulty to visualize the internal sacrum line [8]. In our experience, the bonny shadow interferes with visualization of the S3 foramen. O-arm [7] is slightly more invasive than the formal technique, and recommended as an option in anatomically challenging cases; however, it is not available in many settings.

The first attempt to perform a sacral electrode insertion under CT guidance was reported by Amoroso and colleagues in 2005 [4]. In that series, the researchers found anatomical anomalies in three patients. They performed the PNE test under CT guidance on 30 patients with a 60% response rate [4]. Goos et al. [6], in 2012, reported the use of CT in 51 patients with good results. Of 51 patients who underwent the PNE, the procedure could not be successfully completed in four patients. Testing was positive in 39 of the 47 (83%) patients screened. Meissnitzer and co-authors [9] reported the insertion of sacral electrodes under CT guidance in eight patients. Placement was successful in all patients at the 12-month follow-up. They recommended its use in patients with an altered anatomy of the sacral region, for the prevention of treatment failure.

In our series, we used the CT for electrode placement only in repeated or complicated cases to avoid the trial period again, and in cases of failure due to loss of sensation and anatomical malformation. Nevertheless, CT can be used as a routine method of insertion in every PNE [5]. However, it can complicate the procedure once the CT is not located in the operating theater. In addition, the cost is higher than fluoroscopy.

LIMITATIONS

Our study is notable for several limitations, mostly due to its retrospective design and small number of patients, which were also observed in previous studies. A well-designed prospective, preferably randomized study is recommended to evaluate this point.

CONCLUSIONS

Insertion of sacral electrodes under CT guidance is an effective option, especially in selected cases such as repeated insertion, or failure of primary insertion.

Correspondence

Dr. S. Ginath
Dept. of Obstetrics and Gynecology, Wolfson Medical Center, Holon 58100, Israel
Phone: (972-3) 502-8329
Fax: (972-3) 503-6408
email: ginath@gmail.com

REFERENCES

1. Tanagho EA, Schmidt RA. Bladder pacemaker: scientific basis and clinical future. *Urology* 1982; 20: 614-9.
2. Martellucci J. The technique of sacral nerve modulation. *Colorectal Dis* 2015; 17: O88-94.
3. Rosen A, Taragano L, Condrea A, Sidi A, Ron Y, Ginath S. Effects of sacral neuromodulation on urinary and fecal incontinence. *IMAJ* 2015; 17 (6): 351-5.
4. Amoroso L, Pelliccioni G, Ghiselli R, Scarpino O, Saba V, Ricci S. Sacral-neuromodulation CT-guided. *Radiol Med* 2005; 109: 421-9.
5. Chung CP, Neese PA, Le HK, Bird ET. Computed tomography-guided S3 lead placement for sacral neuromodulation. *Int Urogynecol J* 2013; 24: 349-51.
6. Goos M, Ruf G, Jargon D, et al. [CT-guided electrode placement for sacral nerve stimulation in the treatment of faecal incontinence (cSNS)]. *Zentralbl Chir* 2014; 139 Suppl 2: e63-7. [German].
7. Hellstrom PA, Katisko J, Finnila P, Vaarala MH. Sacral nerve stimulation lead implantation using the O-arm. *BMC Urol* 2013; 13: 48.
8. Martellucci J. Ultrasound-guided tined lead quadripolar electrode placement for sacral nerve modulation. *Colorectal Dis* 2013; 15: 1187.
9. Meissnitzer TS. Trubel, R. Posch-Zimmermann, and M.W. Meissnitzer. CT-Guided Lead Placement for Selective Sacral Neuromodulation to Treat Lower Urinary Tract Dysfunctions. *AJR Am J Roentgenol* 2015; 205: 1139-42.

No, no, you're not thinking, you're just being logical.

Niels Bohr (1885– 1962) Danish physicist who made foundational contributions to understanding atomic structure and quantum theory, for which he received the Nobel Prize in Physics in 1922

It's good to have money and the things that money can buy,
but it's good, too, to check up once in a while and make sure that you haven't lost the things that money can't buy.

George H. Lorimer (1867–1937), American journalist, author and publisher best known as the editor of *The Saturday Evening Post*