Autoimmune Small Fiber Neuropathy: Is There a Place for the Confocal Microscopy?

Natalia Y. Gavrilova MD[1,2], Maria Lukashenko MD[1], Leonid Churilov MD[1,2], and Yehuda Shoenfeld MD FRCP MaACR[1,3,4,5]

[1]St. Petersburg State University, St. Petersburg, Russia [2]St. Petersburg Scientific Research Institute of Phthisiopulmonology, St. Petersburg, Russia
[3]Ariel University, Ariel, Israel [4]Zabludowicz Center for Autoimmune Diseases, Sheba Medical Center, Tel Hashomer, Israel
[5]Laboratory of the Mosaics of Autoimmunity, I.M. Sechenov First Moscow State Medical University of the Ministry of Health of the Russian Federation (Sechenov University), Moscow, Russia

KEY WORDS: chronic fatigue syndrome, confocal microscopy of the cornea, fibromyalgia, small fiber neuropathy, skin biopsy

IMAJ 2022; 24: 271–272

Small fiber neuropathy is an understudied disease, which is characterized by the dysfunction of the smallest nerve fibers that manifests with the sensory and autonomic symptoms. The main diagnostic method is by skin biopsy, the implementation of which has a number of difficulties. Confocal microscopy of the cornea could be an alternative diagnostic method because it is not invasiveness, does not cause pain, is relative simple to perform, and allows automatic analysis.

In 2020, a confocal study of the cornea of three patients was performed. One participant was a healthy control, one presented with fibromyalgia, and one had been diagnosed with chronic fatigue syndrome. The study was performed with a Heidelberg Engineering HRT 2 microscope with Rostock Corneal Module (Germany). In patients with fibromyalgia and chronic fatigue syndrome, a reduced number of fibers with more pronounced branching was observed, which is typical for the small fiber neuropathy. The greater amount of the dendritic cells may allude to the presence of autoimmune pathology. More observations and automatic image analysis are needed to clarify the received data.

Autoimmune, metabolic, genetic, and toxic triggers can lead to the dysfunction of the thinnest nerve fibers that is called small fiber neuropathy (SFN) [1-3]. The most common clinical manifestations include widespread pain and dysautonomia. The diagnosis of the neuropathy includes neurological assessment, skin biopsy with the evaluation of the epidermal nerve fibers, neurophysiological tests (quantitative sensory testing), and small fiber neuropathy – symptoms inventory questionnaire (SFN-SIQ) [3].

Confocal microscopy of the cornea may become a promising tool for the SFN evaluation, because it is not invasive, does not cause pain, is relatively simple to perform, and includes automatic and semi-automatic analysis. Unlike skin biopsies, the repeated analysis of the same part of the cornea also can be performed, which may be useful to evaluate the treatment

Figure 1. Confocal microscopy of the cornea

[A] Healthy control (female, 30 years of age) **[B]** Patient with chronic fatigue syndrome (female, 36 years of age) **[C]** Patient with fibromyalgia (male, 33 years of age)

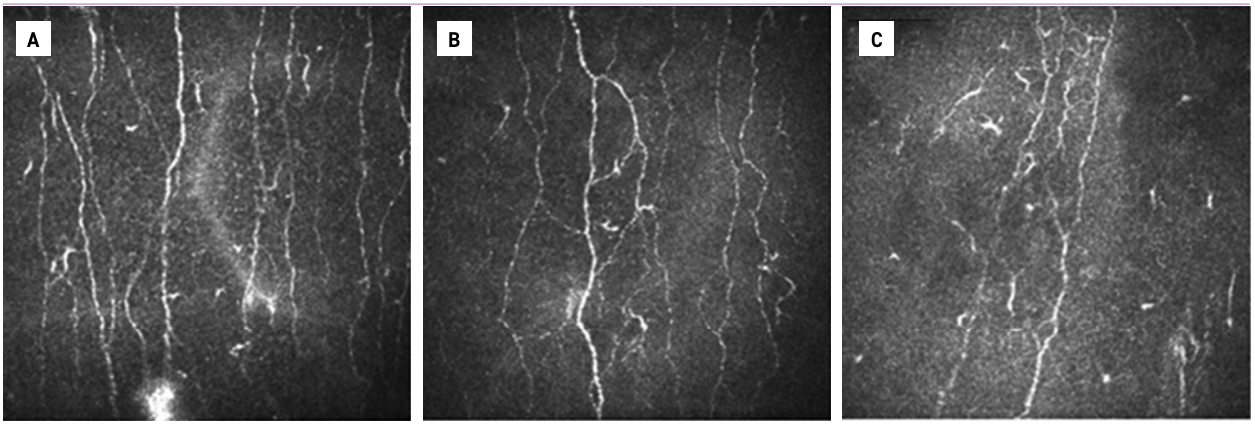

results as well as the disease progression. Visualization of the size and quantity of the dendritic cells may allude to analyze the autoimmune impact in the pathophysiology of the given disease [4,5].

A confocal microscopy analysis was performed in three patients: one with fibromyalgia (male, 33 years of age), one with chronic fatigue syndrome (female, 36 years of age), and one healthy control (female, 30 years of age). All analyses were conducted using a Heidelberg Engineering HRT 2 with Rostock Corneal Module.

The confocal mages are shown in Figure 1.

Figure 1A, the healthy control, shows that nine nerve trunks are evaluated with three branching zones. The fibers lie relatively parallel and have the proper shape without excessive branching. Maximum thickness is 5.2 microns. A relatively small number of dendritic cells can be mentioned, having normal size and shape. In Figure 1B, the results for the patient with chronic fatigue syndrome show five nerve trunks with 17 branches. The average fiber thickness is 2.08 microns. Dendritic cells seem to be slightly larger compared to the healthy volunteer. Figure 1C shows the results of patient with fibromyalgia. There are two nerve trunks, with 21 branches, which is a significantly greater number than in the healthy volunteer. The reduced fiber thickness is observed and reached 2.07 microns. Dendritic cells are more abundant than in a healthy volunteer and have a larger morphology with a blurred outline.

CONCLUSIONS

In patients with fibromyalgia and chronic fatigue syndrome, a reduced number of nerve fibers, which were smaller in diameter and had greater branching, was observed. The changes are characteristics of small fiber neuropathy. The greater number of the dendritic cells may allude the presence of autoimmune pathology. It is necessary to perform more observations and automatic image analysis to confirm our results.

Correspondence

Dr. N. Gavrilova
St. Petersburg State University, St. Petersburg199034, Russia
email: fromrussiawithlove_nb@mail.ru

References

1. Watad A, Bragazzi NL, McGonagle D, et al. Autoimmune/inflammatory syndrome induced by adjuvants (ASIA) demonstrates distinct autoimmune and autoinflammatory disease associations according to the adjuvant subtype: Insights from an analysis of 500 cases. *Clin Immunol* 2019; 203: 1-8.
2. Brouwer BA, Bakkers M, Hoeijmakers JG, Faber CG, Merkies IS. Improving assessment in small fiber neuropathy. *J Peripher Nerv Syst* 2015; 20 (3): 333-40.
3. Brines M, Culver DA, Ferdousi M, et al. Corneal nerve fiber size adds utility to the diagnosis and assessment of therapeutic response in patients with small fiber neuropathy. *Sci Rep* 2018; 8 (1): 4734.
4. Hoitsma E, Reulen JP, de Baets M, Drent M, Spaans F, Faber CG. Small fiber neuropathy: a common and important clinical disorder. *J Neurol Sci* 2004; 227 (1): 119-30.
5. Malik R.A, Kallinikos P, Abbott CA, et al. Corneal confocal microscopy: a noninvasive surrogate of nerve fibre damage and repair in diabetic patients. *Diabetologia* 2003: 46; 683-8.

The ideals which have lighted my way, and time after time have given me new courage to face life cheerfully, have been Kindness, Beauty, and Truth.

Albert Einstein (1879–1955), German-born theoretical physicist who developed the theory of relativity, one of the two pillars of modern physics (alongside quantum mechanics)

Capsule

Effectiveness of COVID-19 vaccines over a 9-month period in North Carolina, USA

Lin et al. extracted data regarding COVID-19-related vaccination and outcomes during a 9-month period (11 December 2020–8 September 2021) for approximately 10.6 million North Carolina (USA) residents. For the two-dose regimens of messenger RNA (mRNA) vaccines, BNT162b2 (30 µg per dose) and mRNA-1273 (100 µg per dose), vaccine effectiveness against COVID-19 was 94.5% (95% confidence interval [95%CI] 94.1–94.9) and 95.9% (95%CI 95.5–96.2), respectively, at 2 months after the first dose and decreased to 66.6% (95%CI 65.2–67.8) and 80.3% (95%CI 79.3–81.2), respectively, at 7 months. Among early recipients of BNT162b2 and mRNA-1273, effectiveness decreased by approximately 15 and 10 percentage points, respectively, from mid-June to mid-July, when the delta variant became dominant. For the one-dose regimen of Ad26.COV2.S (5×1010 viral particles), effectiveness against COVID-19 was 74.8% (95%CI 72.5–76.9) at 1 month and decreased to 59.4% (95%CI 57.2–61.5) at 5 months. All three vaccines maintained better effectiveness in preventing hospitalization and death than in preventing infection over time, although the two mRNA vaccines provided higher levels of protection than Ad26.COV2.S.

N Engl J Med 2022; PMID: 35020982.
Eitan Israeli