Persistent Air Leak and Pneumothorax in COVID-19 Lung Disease Successfully Managed with Endobronchial Valves Deployment

Amir Bar-Shai MD[1,2], Ayal Romem MD MHA[3], and Anna Breslavsky MD[1,2]

[1]Department of Pulmonary Medicine, Barzilai Medical Center, Ashkelon, Israel
[2]Faculty of Health Sciences, Ben-Gurion University of the Negev, Beer Sheva, Israel
[3]Department of Pulmonary Medicine, Meir Medical Center, Kfar Saba, Israel

KEY WORDS: acute respiratory distress syndrome (ARDS), coronavirus disease 2019 (COVID-19), endobronchial valves, persistent air leak, pneumothorax

IMAJ 2022; 24: 339–341

A novel coronavirus was identified in 2019 as the cause of a cluster of pneumonia cases in Wuhan, China. It was named coronavirus disease 2019 (COVID-19). The virus spread rapidly, resulting in a pandemic. The major cause of morbidity and mortality from COVID-19 is largely due acute respiratory distress syndrome (ARDS) [1].

Pneumothorax is one of the complications of COVID-19, which may develop in COVID-19 pneumonia due to multiple plausible mechanisms. The overall incidence of COVID-19 associated pneumothorax has been estimated to be 1%, and among mechanically ventilated COVID-19 patients the incidence rises to 15% [2].

Management of pneumothorax in ventilated patients with ARDS can represent a clinical challenge. While many patients with a persistent air leak (PAL) are expected to recover with supportive care alone, a significant minority require additional interventions. Conservative management, including ventilator strategies to reduce fistula flow, chest tube placement to water seal, home discharge with a one-way valve, or a combination of those, have all been shown to be beneficial in the treatment of PALs. However, in some cases, these strategies are not successful or practical and further interventions are needed. When conservative measures fail, surgical intervention should be considered. Nevertheless, most patients who are on mechanical ventilation have multiple co-morbidities that preclude surgical options. Over the last decade, minimally invasive endoscopic therapies, and one-way endobronchial valves (EBV) in particular, have been successful for management of PAL in this patient population. However, reports of the treatment of COVID-19 associated pneumothorax with PAL are scarce and mostly include conservative management resulting in a high mortality rate. Indeed, case reports have been published describing the use EBV to treat COVID-19 PAL, one of which was as a bridge to definitive surgical management [3,4].

We present the first case in Israel of the use of a one-way EBV (Spiration®-IBV, Olympus, USA) in the successful management of a patient with COVID-19 associated PAL.

PATIENT DESCRIPTION

An 81-year-old man confirmed to have COVID-19 by PCR-test 2 weeks earlier, was brought to our emergency department with cough, dyspnea, and a high-grade fever. Prior to his current illness, the patient was physically active and was still working as the director of a humanitarian equipment transportation company. His past medical history included diabetes, hypertension, anterior resection, and chemotherapy d/t rectal adenocarcinoma in 2018.

On arrival the patient was noted to be tachypnoeic with a respiratory rate of 32 breaths/minute, febrile at 38.2°C, normotensive at 115/65 mmHg, and hypoxic with oxygen saturations of 65% on room air, and 78% on a non-rebreather oxygen mask. Chest examination revealed bilateral basal crackles. A chest radiograph showed diffuse bilateral infiltrates consistent with a diagnosis of COVID-19 pneumonia [Figure 1A].

He was intubated and ventilated, and initially treated as per the local protocol for COVID-19. Three days following his admission, computed tomography (CT) angiography was conducted to rule out pulmonary embolism; however, subcutaneous emphysema and a pneumomediastinum were observed in addition to bilateral ground glass opacities, crazy paving, and consolidations [Figure 1B]. As the patient remained ventilator dependent he underwent an uneventful bedside tracheostomy. Five days later an acute clinical deterioration was observed and a chest X-ray revealed a tension pneumothorax of the right hemithorax [Figure 1C]. Tube thoracostomy was performed, with stabilization of his parameters. Connection of

Figure 1. Abnormalities on chest imaging of the patient. Chest radiographs show that pneumothorax and endobronchial valve deployment resulted in resolution of the pneumothorax

[A] Chest radiography performed on admission. Bilateral patchy densities, hilar interstitial infiltrates, and coalescing consolidation in the left lower lung are clearly visible

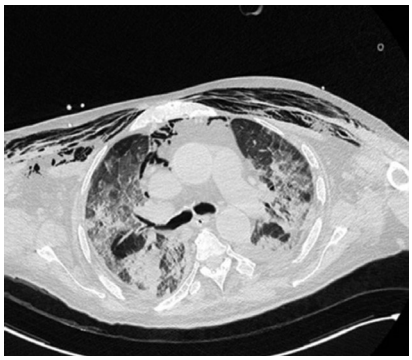

[B] Chest computed tomography on day 3 after admission shows subcutaneous emphysema and a pneumomediastinum, with bilateral ground glass opacities, crazy paving, and bilateral consolidation

[C] Chest radiography performed during the patient's acute deterioration shows a large lucency occupying the entire right hemithorax with contralateral mediastinal shift, right hemi diaphragm flattening and right lung compressive atelectasis, consistent with right tension pneumothorax

[D] Follow-up radiography showed that the right lung had not reexpanded due to persistent air leak. Right pneumothorax was still demonstrated, although a chest tube connected to a digital suction device (THOPAZ®) is localized in the right pleural space

[E] Bronchoscopic image demonstrating occlusion of the apical (RB1) and anterior (RB3) segments of the right upper lobe, by IBV-Spiration one-way endobronchial valves

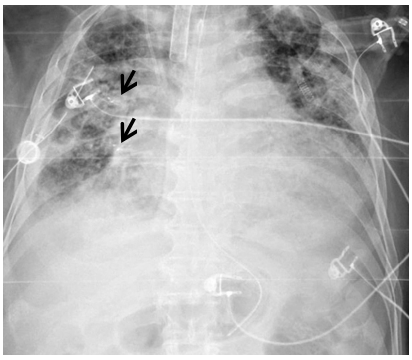

[F] Post-procedure radiography shows resolution of pneumothorax with only a one-way Heimlich valve. Four endobronchial valves are demonstrated in the right lung (arrows)

the chest tube to a digital suction device (THOPAZ®, Medela, USA), confirmed the presence of a large air leak of more than 3.5 liters/minute. An attempt at conservative management, applying low-tidal volumes and low positive end-expiratory pressure settings failed to show any improvement in the severity of the air leak [Figure 1D]. Thus, a decision was made to address the PAL by utilizing a minimally invasive endoscopic treatment approach using one-way EBV.

In collaboration with the department of pulmonary medicine, Meir Medical Center, we performed sequential balloon occlusion through flexible bronchoscopy, which enabled us to localize the air leak to regions of the right upper lobe (RUL) and the right middle lobe (RML). Occlusion of the apical (RB1) and anterior (RB3) segments of the RUL and the lateral segment bronchus (RB4) and medial segmental bronchus (RB5) of the right middle lobe with four IBV-Spiration valves resulted in a reduction of the air leak from 4000 ml\min to 290 ml\min [Figure 1E]. Five days after the procedure, the chest tube was disconnected from the digital suctioning device and replaced with a Heimlich valve, with no pneumothorax observed [Figure 1F]. The patient participated in an in-patient rehabilitation program.

COMMENT

Despite the recent introduction of effective vaccines, the COVID-19 pandemic is continuing to take its toll on the global population with nearly 98 million confirmed cases and more than 2.3 million deaths recorded as of 8 February 2021.

Although the diversity of symptoms and signs associated with the COVID-19 infection has been thoroughly described in the literature, only recently has the unique complication of COVID-19 associated pneumothorax been described and better characterized. The term spontaneous pneumothorax refers to the presence of air in the pleural space that is not caused by trauma or other precipitating factor (mostly medical procedure). COVID-19 associated pneumothorax should be regarded as one form of secondary spontaneous pneumothorax (SSP). A certain proportion of these patients will present with a PAL defined as abnormal connections between the alveoli or bronchi and the pleural space that fail to resolve despite constant drainage of the thoracic cavity for more than 5 to 7 days. Pneumothorax and PALs among patient with ARDS in general, and specifically severe COVID-19 patients, could have detrimental effects on patient outcomes, including added morbidity, prolongation of mechanical ventilation, ventilator associated pneumonia and higher mortality rates.

Correspondence

Dr. A. Bar-Shai
Dept. of Pulmonary Medicine, Barzilai Medical Center, Ashkelon 7830604, Israel
Phone: (972-8) 674-5466
Fax: (972-8) 674-5473
Email: amirb@bmc.gov.il; amirbs@tlvmc.gov.il

References

1. Zhu N, Zhang D, Wang W, et al. A novel coronavirus from patients with pneumonia in China, 2019. *N Engl J Med* 2020; 382 (8): 727-33.
2. Udi J, Lang CN, Zotzmann V, et al. Incidence of barotrauma in patients with COVID-19 pneumonia during prolonged invasive mechanical ventilation-a case-control study. *J Intensive Care Med* 2021; 36 (4): 477-83.
3. Szewczyk J, Adkinson BC, Akkineni S, Nguyen DM, Arias SA, Villamizar NR. Endobronchial valves: a bridge to definitive surgical management in COVID-19 recurrent pneumothorax. *J Thorac Dis* 2021; 13 (1): 411-13.
4. Pathak V, Waite J, Chalise SN. Use of endobronchial valve to treat COVID-19 adult respiratory distress syndrome-related alveolopleural fistula. *Lung India* 2021; 38 (Suppl): S69-S71.
5. Elder C, Bawa S, Anderson D, et al. Expectant management of pneumothorax in intubated COVID-19 positive patients: a case series. *J Cardiothorac Surg* 2020; 15 (1): 263.

Capsule

Cyclical respiratory motion inhibits viral infection

Breathing does more than just ensure the oxygenation of an animal's tissues. With its dynamic and regular mechanical forces, breathing has been implicated in all sorts of processes, including lung development and regulation of immune responses. **Bai** et al. used a human lung alveolus chip microfluidic device that recapitulates human airway physiology to model H3N2 influenza infection. They found that cyclical respiratory motion inhibits viral infection by activating the mechanosensitive ion channel TRPV4, which then induces lung epithelium and endothelium to produce S100 alarmin proteins. These mediators bind the pattern recognition receptor RAGE, which triggers several innate immune response programs that help combat virus. Intriguingly, a TRPV4 inhibitor was able to reduce both inflammation and viral loads, suggesting that this may be a useful approach for the treatment of viral pneumonia.

Nat Commun 2022; 13: 1928
Eitan Israeli

Capsule

Intramuscular AZD7442 (Tixagevimab-Cilgavimab) for prevention of COVID-19

The monoclonal-antibody combination AZD7442 is composed of tixagevimab and cilgavimab, two neutralizing antibodies against severe acute respiratory syndrome coronavirus 2 (SARS-CoV-2) that have an extended half-life and have been shown to have prophylactic and therapeutic effects in animal models. Pharmacokinetic data in humans indicate that AZD7442 has an extended half-life of approximately 90 days. A total of 5197 participants underwent randomization and received one dose of AZD7442 or placebo (3460 in the AZD7442 group and 1737 in the placebo group). **Levin** and colleagues conducted the primary analysis after 30% of the participants had become aware of their randomized assignment. In total, 1221 of 3461 participants (35.3%) in the AZD7442 group and 593 of 1736 participants (34.2%) in the placebo group reported having at least one adverse event, most of which were mild or moderate in severity. Symptomatic COVID-19 occurred in 8 of 3441 participants (0.2%) in the AZD7442 group and in 17 of 1731 participants (1.0%) in the placebo group (relative risk reduction, 76.7%; 95% confidence interval [95%CI] 46.0–90.0; $P < 0.001$); extended follow-up at a median of 6 months showed a relative risk reduction of 82.8% (95%CI 65.8–91.4). Five cases of severe or critical COVID-19 and two COVID-19-related deaths occurred, all in the placebo group.

N Engl J Med 2022; DOI: 10.1056/NEJMoa2116620
Eitan Israeli